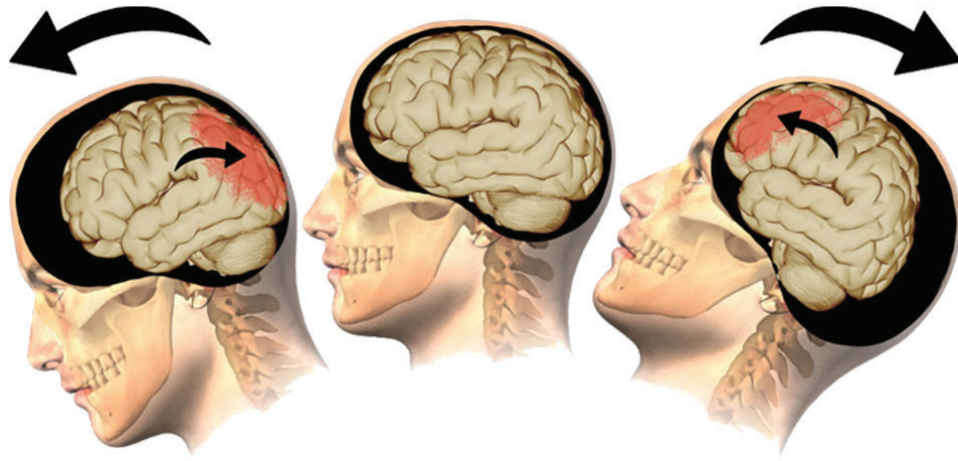
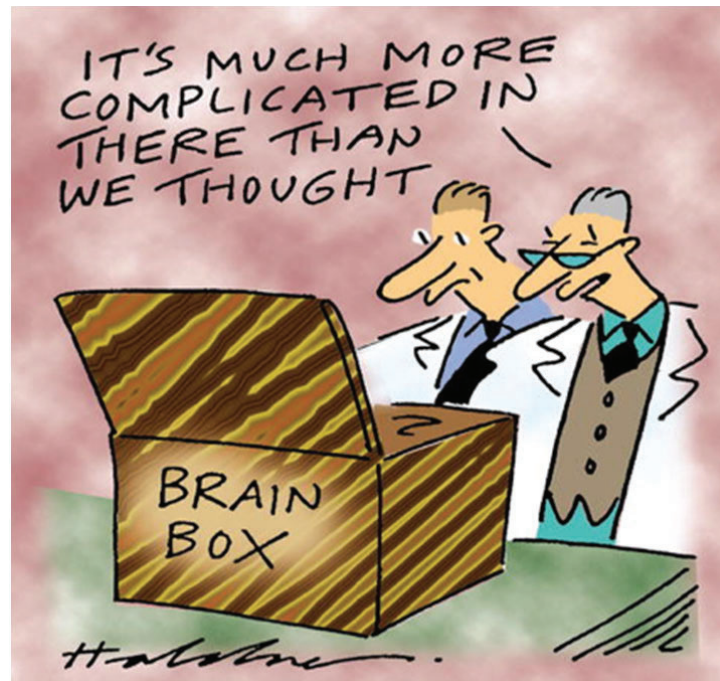


Litigating Brain Injury Cases

Thomas A. Crosley
tom@crosleylaw.com



TBI Deficits

Attention Deficits

Loss of train of thought

Fatigue

Anxiety

Depression

Dizziness

Headache

Memory problems

Planning and decision
making difficulties

Irritability

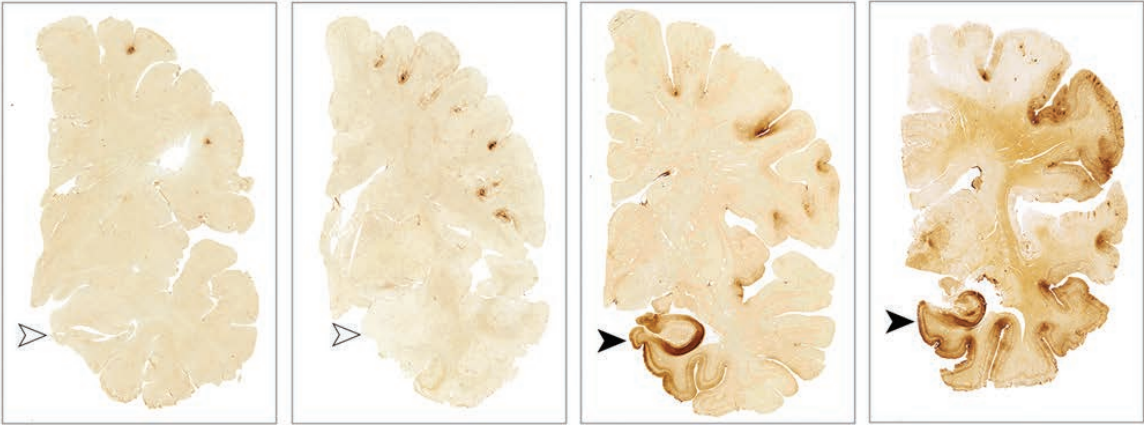
Trouble finding words

Mental "fogginess"

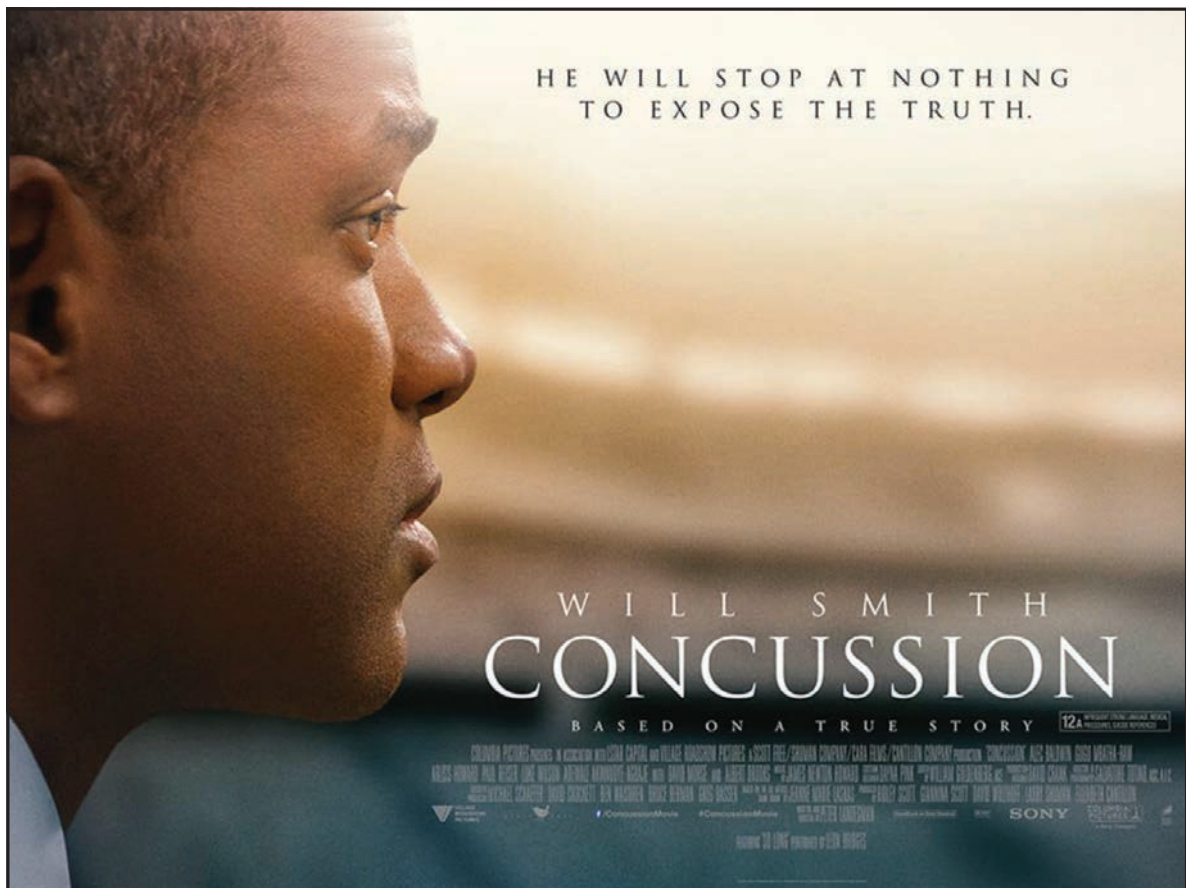


Chronic Traumatic Encephalopathy (CTE)

Stage I CTE Stage II CTE Stage III CTE Stage IV CTE



The image displays four coronal sections of a human brain, illustrating the progression of Chronic Traumatic Encephalopathy (CTE) from Stage I to Stage IV. Each section is labeled above it. Stage I shows minimal pathology with a few small brown spots. Stage II shows more numerous brown spots. Stage III shows significant pathology with large, dense brown areas and a black arrowhead pointing to a large, dark, irregular mass in the temporal lobe. Stage IV shows severe pathology with extensive, dense brown areas and a black arrowhead pointing to a large, dark, irregular mass in the temporal lobe.



Find the full text of this and thousands of other resources from leading experts in dozens of legal practice areas in the [UT Law CLE eLibrary \(utcle.org/elibrary\)](https://utcle.org/elibrary)

Title search: Litigating Brain Injury Cases

First appeared as part of the conference materials for the
2019 Car Crash Seminar session
"Litigating Traumatic Brain Injury Cases"